

Hepatoprotective activity of aerial parts of plant extract of *Callicarpa macrophylla* in rats

Ramesh Patel^{1*} and Talha Jawaid²

Department of Pharmacology, Hygia Institute of Pharmaceutical Education and Research, Ghazipur Balram, Ghaila Road, Faizullaganj, Lucknow, (U.P.) India.

Accepted 4 April, 2014

ABSTRACT

This paper evaluates the hepatoprotective activity of the aqueous alcoholic (60%) extract of the aerial parts of *Callicarpa macrophylla* (Verbenaceae) against Paracetamol and carbon tetrachloride induced hepatotoxicity. The powder of the aerial parts was extracted with aqueous alcoholic (60%) and the resultant extract was subjected for phytochemical analysis to identify different phytoconstituents. Preliminary phytochemical investigation showed the presence of flavonoids, tannins, steroids, triterpenes and saponins, as major secondary metabolites. Some of the physiochemical parameters such as ash value, extractive value and loss on drying were also studied. Hepatoprotective activity of extract was studied against Paracetamol (3 g/kg b.w./p.o. 3 days) and carbon tetrachloride (2 ml/kg, b.w. /S.C. 4 days) induced hepatotoxicity. Standard drug was used for hepatoprotection (Silymarin 25 mg/kg, b.w./p.o.). Treatment of animal with hydro-alcoholic extract of aerial parts of *C. macrophylla* significantly ($p < 0.05$) decreased the levels of SGOT in serum which is an indicative of hepatoprotective activity. Also brought down was the level of serum glutamic pyruvic transaminase (SGPT) significantly ($p < 0.05$ in 200 mg/kg b.w. and $p < 0.01$ in 100 mg/kg b.w. doses). Other than these parameters level of Bilirubin (Total and Direct) and histopathological studied also was indicative of hepatoprotective property of the plant extract. In conclusion, it is observed that hydro-alcoholic extract of aerial parts of *C. macrophylla* possess hepatoprotective property which was evident by biochemical parameters and histopathological reports.

Keywords: Hepatoprotective activity, aerial part, *Callicarpa macrophylla*, anti-inflammatory activity.

*Corresponding author. E-mail: ramesh.bfarm@gmail.com.

INTRODUCTION

Herbal drugs play major role in the treatment of hepatic disorders. A number of medicinal plants and their formulations are widely used for the treatment of these disorders (Praveen et al., 2009). *Polycarpa macrophylla* Priyangoo is a member of the Verbenaceae Family. The parts of this plant are used to cure many diseases such as rheumatic pains and stomach disorders, heal cut and wounds, digestion and abdominal trouble, diabetes, skin diseases, fever, pitta, (In Indian Herbal medicinal system related to liver disease) vomiting etc. The leaves are used in gout and rheumatic pain (Billore and Dennis, 2005). Decoctions of the leaves are used in the treatment of diarrhoea, dysentery and arresting bleeding. A juice

made from leaves is used in gastric trouble, headache and stop bleeding (Au et al., 2008).

The phytochemical screening of the plant revealed the presence of different type of chemical like seeds contain oleanolic acid. Besides diterpenoids, leaves contain favonoids, C₂₂-C₂₄ fatty acids, Calliterpenone monoacetate and Calliterpenone isopropylidene derivative. Calliphyllin, betulinic acid, 5,4'-dihydroxy-3,7,3'-trimethoxyflavone, 5,4'-dihydroxy-3,7,-trimethoxyflavone & β -sitosterol are present in the leaves (Talapatra et al., 1994). Diterpene (Calliterpenone) (Fujita et al., 1950), Diterpenoids (16 α ,17-Isopropylideno-3-oxo-phylloladane (Singh and Pawan, 1994); (3 β , 16 α , 17-trihydroxy-

Table 1. Effects of Hydro-alcoholic extract of aerial parts of *Callicarpa macrophylla* on SGPT, SGOT and Bilirubin level in Paracetamol induced hepatotoxicity in rats.

Group	Treatment
I	Normal control received only vehicle (0.5% CMC) 1 mg/kg once daily for 3 days.
II	PCM 3 g/kg once daily for 3 days.
III	PCM + Silymarin 25 mg/kg once daily for 3 days.
IV	PCM + Plant hydro-alcoholic extract (100 mg/kg)
V	PCM + Plant hydro-alcoholic extract (200 mg/kg) (Mujeeb et al., 2009)

Phyllocladane) (Singh and Pawan 1994), flavanoids (β -sitosterol, ursolic acid, luteolin and apigenin) (Subramanian et al., 1974), 16,17-dihydroxy-kauranoids (Agrawal et al., 1995), fatty acids and other constituents (Upadhyaya, 2006).

In view of the above, the present study was carried out with the aim of evaluating the hepatoprotective properties of the extract aerial parts of the aerial part of *Callicarpa macrophylla*. In experimental rat model of liver injury was induced by Paracetamol and carbon tetrachloride.

MATERIALS AND METHODS

Drugs and chemicals

Silymarin was a gift sample from Mepra Laboratories, Mumbai, India. SGPT, SGOT, TOTAL and DIRECT BILIRUBIN were estimated as per the standard procedure prescribed by the manufacturer's instruction manual provided in kit (ERBA Diagnostics Baddi, Solan (HP), India. All other chemicals and reagents used were of analytical grade.

Collection and authentication of plant material

The aerial parts of *C. macrophylla* used for the present studies were collected from Central Medicinal and Aromatic Plant (Lucknow), India. The plant was identified, confirmed and authenticated by National Botanical Research Institute (Council of Scientific and Industrial Research) Lucknow-226001, India (Ref. No: NBRI/CIF/262/2011). The aerial parts were cut into small pieces and shade dried. The dried material was then pulverized separately into coarse powder by a mechanical grinder. The resulting powder was then used for extraction.

Preparation of hydro-alcoholic extract

The powdered drug was dried and packed well in soxhlet apparatus and extracted (48 h) with petroleum ether (60 to 80°C) for defatting and the resulting powdered dried and extracted with 60% ethanol by using soxhlet apparatus, for 24 h. The extract was concentrated and dried using rotary evaporator (Yadav et al., 2011). It was stored in refrigerator and kept in desiccator few hours before use.

Experimental animals

Wistar albino rats of either sex (M/F) weighing between (150 to 200 \pm 20 g) were procured from the Central Drug Research Institute

Lucknow, Uttar Pradesh. The animals were acclimatized for seven days under laboratory conditions (Raj et al., 2010). The animals fed with commercially available rat pellet diet (Ashirwad industries, Tirpari Kharar Dstt. Monali, P 8). Water was allowed *ad libitum* under strict hygienic conditions. The study protocols were duly approved by the Institutional Animal Ethics Committee (IAEC), (approval no. Hygia\M.Pharm\17\2011-12) of Studies were performed in accordance with the CPCSEA guidelines.

Hepatoprotective activity induced by Paracetamol

Albino rats (Wistar Strain) of either sex weighing (150 to 200 \pm 20 g) were selected and divided into five groups of five animals each (Table 1, Figures 1 to 4).

All the above mentioned dosages were given once daily three days. Animals were treated as shown above for the period of three days. At the end of every day, PCM (3 mg/kg body weight, P.O. 0.5% CMC) was administered to all groups except group I. Group II received Paracetamol to induced hepatotoxicity as diseased control group. Group III received Silymarin 25 mg/kg, P.O. once a day and Paracetamol as mentioned above. Whereas group IV was treated with test extract at dose of 100 mg/kg, and group V treated with Hydro-alcoholic fraction of 200 mg/kg respectively. During this period of treatment, the rats were maintained under normal diet and water. All the animals were sacrificed 24 h after the last dose of Paracetamol at the end of 3rd day. Animals were sacrificed by cervical dislocation and blood sample was collected in EDTA coated tube by heart puncture. Blood was allowed at room temperature for 30 min, then subjected to centrifugation (3000 rpm for 15 min) and serum was collected for the determination of biochemical parameters (SGPT, SGOT, total and direct bilirubin) using U-V visible spectrophotometer and diagnostic kits. Liver was dissected out. Further liver was placed in 10% formalin solution for histopathological study.

Histopathological studies of the liver in Paracetamol induced hepatotoxicity

The histopathological evaluation of Paracetamol toxicity in all the groups was examined and shown in Figure 5. The description is as follows: Section of rat liver treated with vehicle control group shows well maintained trebaecular structure of liver tissue. Inter trebaecular spaces shows presence of red blood cells. Few cells show vesicular. Mild lymphocytic infiltration was seen. Bile ducts and Kupffer cells show normal appearance. Normal blood vessels were seen. Only occasional thin bands of fibrous tissue were seen in between lobules of liver tissue.

Section of liver in toxicant control group shows blurred trebaecular structure of liver with increased inters trebaecular spaces. Cellular outline of hepatocytes was irregular, cytoplasm was eosinophilic and granular with hyaline degeneration at few




Figure 1. Serum glutamic pyruvic transaminase, SGPT (IU/L). Values are expressed as mean \pm S.E.M. (n = 5) one way ANOVA followed by Dunnett test. * P value < 0.05, **P value < 0.01, ***P value < 0.001 compared with toxic group.

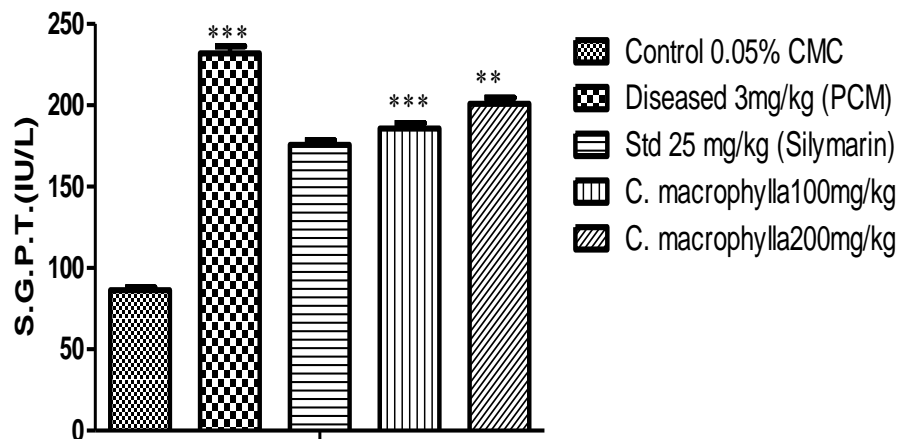


Figure 2. Serum glutamic oxaloacetic transaminase, SGOT (IU/L). Values are expressed as mean \pm S.E.M. (n = 5) one way ANOVA followed by Dunnett test. * P value < 0.05, **P value < 0.01, ***P value < 0.001 compared with toxic group.

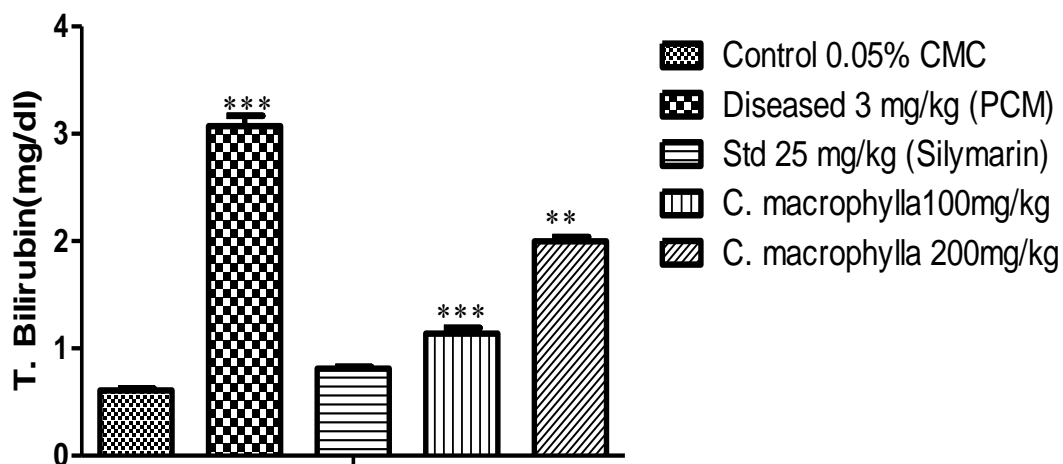


Figure 3. Total bilirubin (mg/dl). Values are expressed as mean \pm S.E.M. (n = 5) one way ANOVA followed by Dunnett test. *P value < 0.05, **P value < 0.01, ***P value < 0.001 compared with toxic group.

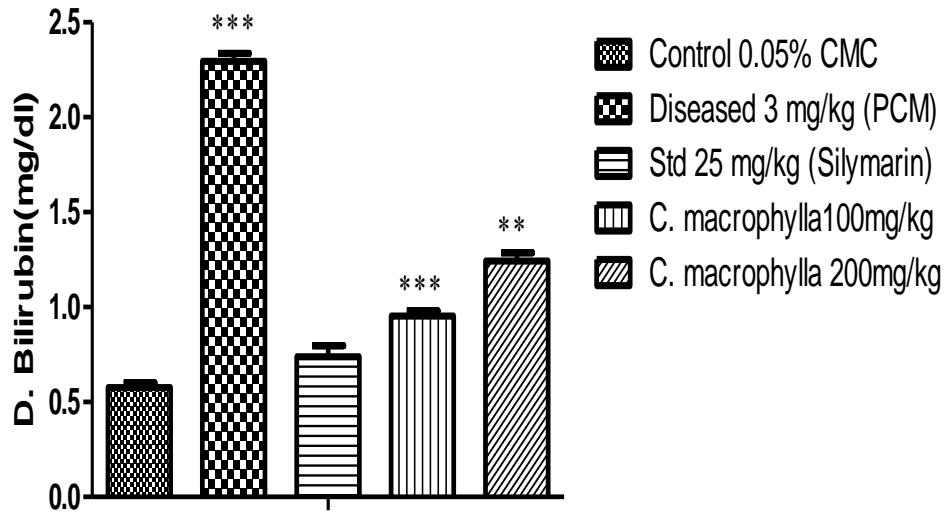


Figure 4. Direct bilirubin (mg/dl). Values are expressed as mean \pm S.E.M. (n = 5) one way ANOVA followed by Dunnett test. *P value < 0.05, **P value < 0.01, ***P value < 0.001 compared with toxic group.

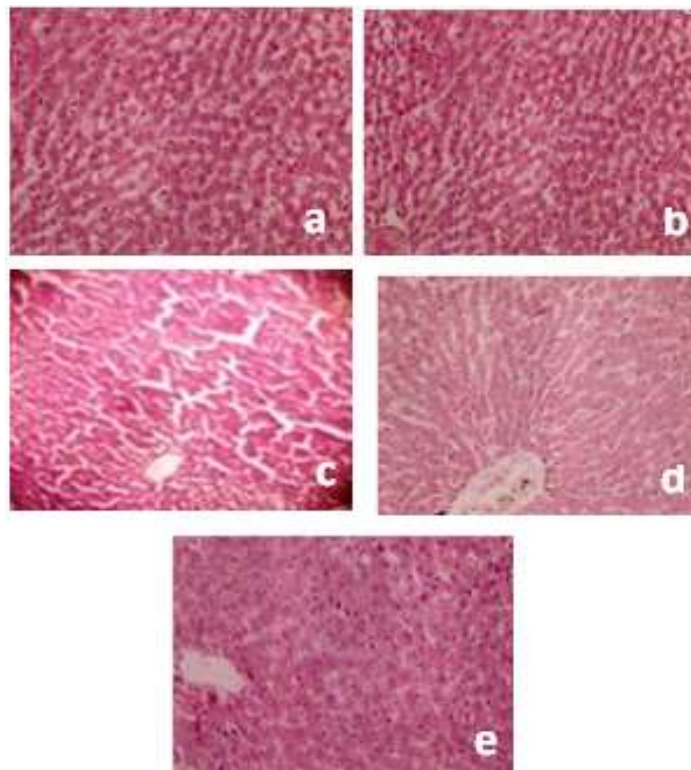


Figure 5. (a) Negative control (0.5% CMC); (b) Positive control (3 g/kg PCM); (c) Silymarin (25 mg/kg) + PCM; (d) Extract (100 mg/kg) + PCM; (e) Extract (200 mg/kg) + PCM.

places and nucleus was vesicular and shows clumping of chromatin. Kupffer cells show proliferation. There was mild to moderate diffused lymphocytic infiltration. Occasional pigment

laden macrophages were seen. Few thick bands of fibrous tissue were seen in between lobules of liver with occasional dilated blood vessels.

Table 2. Effects of hydro-alcoholic extract of aerial parts of *Callicarpa macrophylla* on SGPT, SGOT and bilirubin level in carbon tetrachloride induced hepatotoxicity in rats.

Group	Treatment	SGPT (IU/L)	SGOT (IU/L)	Bilirubin (mg/dl)	
				Total	Direct
I	Control (0.1 N normal saline)	70.55 ± 4.09	115.65 ± 6.10	0.64 ± 0.03	0.59 ± 0.02
II	CCl ₄ (2 ml/kg)	178.35 ± 5.55	319.03 ± 4.34	3.84 ± 0.07	2.45 ± 0.02
III	CCl ₄ + Silymarin (25 mg/kg)	112.12 ± 4.09	196.00 ± 3.35	0.83 ± 0.02	0.99 ± 0.02
IV	CCl ₄ + Extract (100 mg/kg)	128.40 ± 2.56	253.24 ± 3.88	1.06 ± 0.05	1.084 ± 0.03
V	CCl ₄ + Extract (200 mg/kg)	142.18 ± 5.67	269.87 ± 4.25	1.76 ± 0.08	1.24 ± 0.05

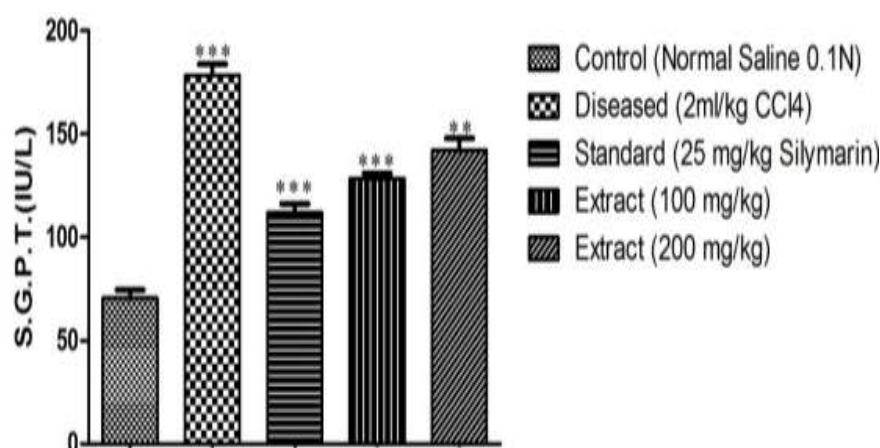


Figure 6. Serum glutamic pyruvic transaminase, SGPT (IU/L). Values are expressed as mean ± S.E.M. (n = 5) one way ANOVA followed by Dunnett test. *P value < 0.05, **P value < 0.01, ***P value < 0.001 compared with toxic group.

Section of liver Silymarin treated group shows normal hepatic cell, each with well preserved cytoplasm, prominent nucleus and nucleolus, brought out central vein. Bile duct and Kupffer cells show mild degeneration. Blood vessels show normal appearance. Thick band of fibrous tissue were seen in between lobules of liver.

Section of liver treated with extract (100 mg/kg) shows complete restoration of trebaeacular structure of liver. It was more pronounced at the periphery. Most of the hepatocytes show normal appearance but occasional cells show hyaline degeneration of cytoplasm and irregular clumping of nuclei. Kupffer cells were nearly normal. Mild lymphocytic infiltration was seen.

Blood vessels show normal appearance. Only occasional bands of fibrous tissue were seen in between lobules of liver tissue.

Section of liver treated with extract (200 mg/kg) shows blurred trebaeacular structure of liver. Patchy area of hyaline degeneration of cytoplasm and irregular clumping of chromatin of nuclei was seen. Occasional dilated blood vessels were seen. Occasional bands of fibrous tissue were also seen.

Evaluation of hepatoprotective activity in carbon tetrachloride induced hepatotoxicity

The aerial parts of hydro-alcoholic fraction of *C. macrophylla* significantly decrease the increased biochemical parameters such as serum glutamic oxaloacetic transaminase (SGOT), serum glutamic pyruvic transaminase (SGPT), total and direct bilirubin due

to CCl₄ administration which evident in Table 2 and Figures 6 to 9 (Manokaran et al., 2008).

RESULTS AND DISCUSSION

Estimation of serum marker enzymes

During hepatic damage, cellular enzymes like AST, ALT and ALP present in liver cells leak into the serum, resulting in increased concentrations (Bhanwra et al., 2000).

In the current study, treatment of rats with Hydro-alcoholic-extract of aerial parts of *C. macrophylla* significantly ($p < 0.05$ in 200 mg/kg b.w. and $p < 0.001$ in 100 mg/kg b.w.) decreased the levels of SGPT in serum which is an indication of hepatoprotective activity. Bilirubin is one of the most useful clinical clues to the severity of necrosis and its accumulation is a measure of binding, conjugation and excretory capacity of hepatocyte. Decrease in serum bilirubin after treatment with the extract in liver damage induced by Paracetamol, indicated the effectiveness of the extract in normal functional status of the liver.

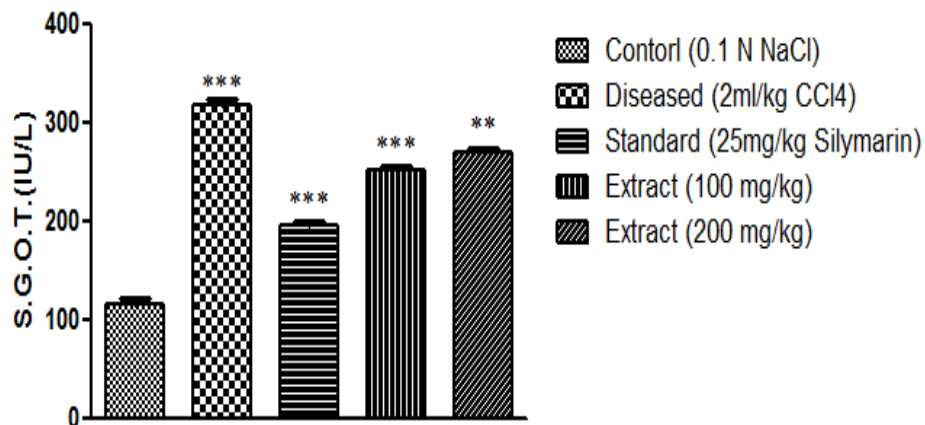


Figure 7. Serum glutamic oxaloacetic transaminase, SGOT (IU/L). Values are expressed as mean \pm S.E.M. (n = 5) one way ANOVA followed by Dunnett test. *P value < 0.05, **P value < 0.01, ***<P value < 0.001 compared with toxic group.

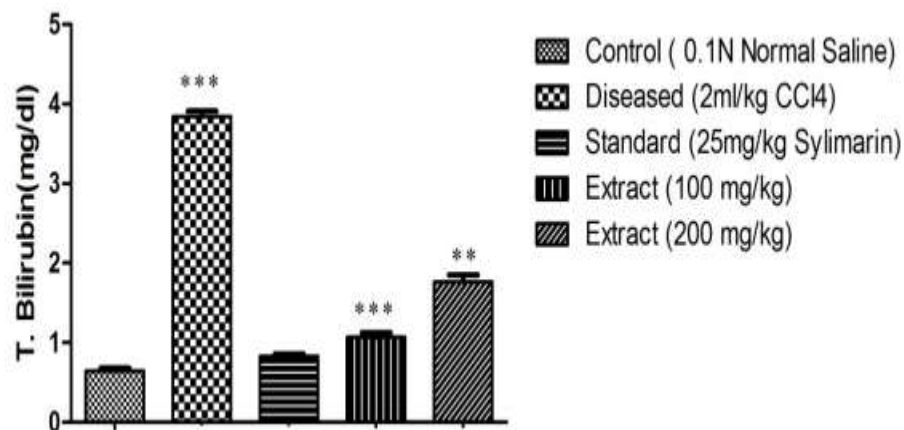


Figure 8. Total bilirubin (mg/dl). Values are expressed as mean \pm S.E.M. (n = 5) one way ANOVA followed by Dunnett test* P value < 0.05, **P value < 0.01,***P value < 0.001 compared with toxic group.

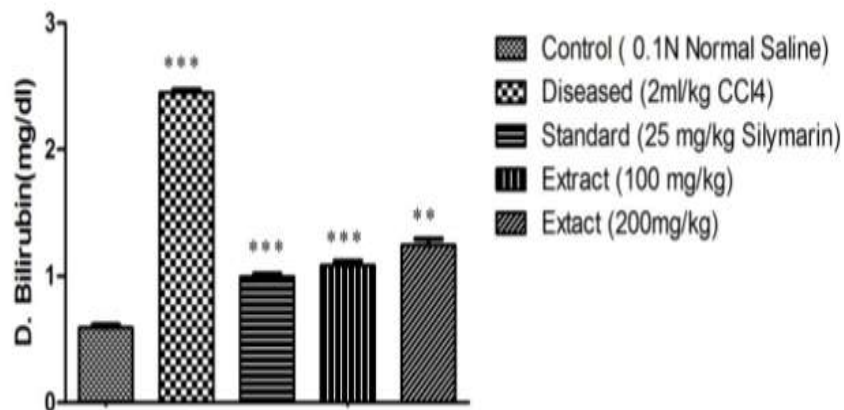


Figure 9. Direct bilirubin (mg/dl). Values are expressed as mean \pm S.E.M. (n = 5) one way ANOVA followed by Dunnett test. *P value<0.05,**P value < 0.01,***P value < 0.001 compared with toxic group.

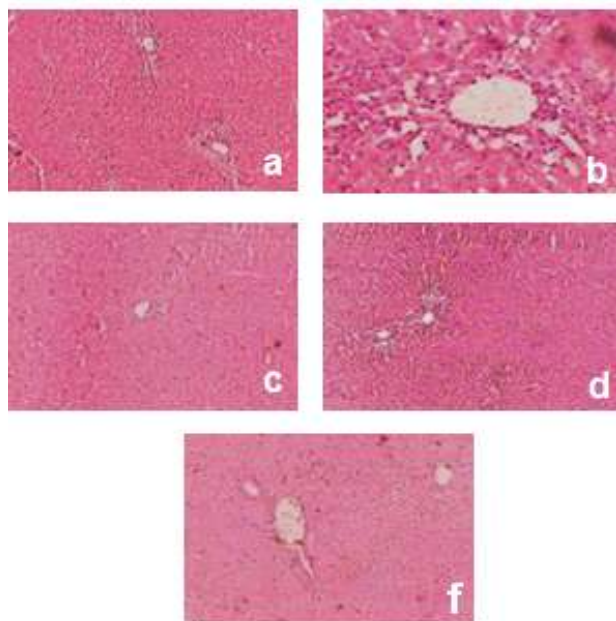


Figure 10. (a) Negative control; (b) positive control (normal saline 0.2 ml/100 g) (2 ml/kg CCl₄); (c) Silymarin (25 mg/kg) + CCl₄; (d) Extract (100 mg/kg) + CCl₄; (e) Extract (200 mg/kg) + CCl₄.

Biochemical parameters

The hydro-alcoholic extract of aerial parts of *C. macrophylla* significantly decreased the increased biochemical parameters such as serum glutamic oxaloacetic transaminase (SGOT), serum glutamic pyruvic transaminase (SGPT), total and direct bilirubin in (Table 2, Figure 10) due to CCl₄ administration. Hydro-alcoholic-extract of aerial parts of *C. macrophylla* 200 mg/kg show moderate significant activity, and 100 mg/kg show significant activity when compared to CCl₄ control group (Table 2).

Histopathological parameters

The hydro-alcoholic extract of aerial parts of *C. macrophylla* may exert their hepatoprotective activity through the presence of flavonoids; since flavonoids are found to be present as chemical constituents of aerial parts of *C. macrophylla*, by phytochemical screening (Whitcomb and Block, 1994). Hence they may be responsible to possess hepatoprotective activity against CCl₄ induced hepatotoxicity. The CCl₄ which is inactive transformed to a free radical through the microsomal cytochrome P-450 dependent enzyme, resulting in activation of trichloromethyl free radical which causes liver toxicity. An additional and important factor in the antihepatotoxicity activity of any drug is the ability of its

constituents to inhibit the aromatase activity of cytochrome P-450, thereby favouring liver regeneration.

On that basis, it is suggested that the presence of flavonoids in hydro-alcoholic extract of aerial parts of *C. macrophylla* may be a factor to contribute antihepatotoxicity ability through inhibition of cytochrome P-450 aromatase (Kukongviriyapan et al., 2003).

Conclusion

Hydro-alcoholic extract of Aerial parts of *C. macrophylla* possess hepatoprotective property which was evident by biochemical parameters and histopathological reports.

REFERENCES

- Agrawal PKB, Singh V, Anil K, 1995. NMR chemical shift correlation in 16, 17-dihydroxy-kauranoids implication for stereochemical assignments. *Phytochemistry*, 39(4):929-930.
- Au DT, Wu J, Jiang Z, Chen H, Lu G, Zhao Z, 2008. Ethanobotanical study of medicinal plants used by Hakha in Guandong China. *J Ethnopharmacol*, 117:41-50.
- Bhanwra S, Singh J, Khoosla P, 2000. Effect of *Azadirachata indica* leaf aqueous extract on paracetamol induced liver damage in rats. *Indian J Physiol Pharmacol*, 44(1):64-68.
- Billore KV, Dennis TJ, 2005. Database on medicinal plants used in Ayurveda. Central Council for Research in Ayurveda and Siddha, New Delhi, 7:353-355.
- Fujita EOM, Ichida I, Chatterjee A, Deshmue SK, 1950. Confirmation of the structure of calliterpenone, a diterpene from *Callicrpa macrophylla* Vahl. *Phytochemistry*, 4:568.
- Kukongviriyapan V, Janyacharoen T, Kukongviriyapan U, Laupattarakasae P, Kanokmedhakul S, Chantaranonthai P, 2003. Hepatoprotective and antioxidant activities of *Tetracera loureiri*. *Phytother Res*, 17:717-721.
- Manokaran S, Jaswanth A, Sengottuvelu S, Nandhakumar J, Duraisamy R, Karthikeyan D, Mallegaswari R, 2008. Hepatoprotective activity of *Aerva lanata* Linn. against Paracetamol induced hepatotoxicity in rats. *Res J Pharm Tech*, 1(4):398-400.
- Mujeeb M, Aeri V, Khan SA, 2009. Hepatoprotective activity of the methanolic extract of the *Tylophora indica* (Brum F.) Meril leaves. *Int J Green Pharm*, 3(2):125-127.
- Praveen TK, Dharmaraj S, Bajaj J, Dhanabal SP, Manimaran S, Nanjan MJ, Razdan R, 2009. Hepatoprotective activity of petroleum ether, diethyl ether and methanol extract of *Scoparia dulcis* L. against carbon tetrachloride induced acute liver injury in mice. *Indian J Pharmacol*, 41(3):110-114.
- Raj VP, Chandrasekhar RH, P V, S A D, Rao MC, Rao VJ, Nitesh K, 2010. In vitro and in vivo hepatoprotective effects of the total alkaloid fraction of *Hygrophila auriculata* leaves. *Indian J Pharmacol*, 42(2):99-104.
- Singh AKA, Pawan K, 1994. 3β,16α, 17-trihydroxyphylloladane, A diterpenoid obtain after microbial transformation of the aqueous extract of *Callicrpa macrophylla*. *Phytochemistry*, 37(2):587-588.
- Singh AKA, Pawan K, 1994. 16α, 17-Isopropylidene-3-oxo-Phyllocladane, A Diterpenoid from *Callicrpa macrophylla*. *Indian J Chem*, 33B:717-721.
- Subramanian SS, Nair AGR, Vedantham TNC, 1974. Terpenoids and flavones of *Callicrpa macrophylla* and *Callicrpa longifolia*. *Phytochemistry*, 13:306-307.
- Talapatra SK, Polley M, Talapatra B, 1994. Calliphyllin, a new diterpene from the leaves of *Callicrpa macrophylla*. *J Indian Chem Soc*, 71:527-553.
- Upadhyaya KA, 2006. Ateeque, isolation of fatty acid and other

- constituents from *Callicrpa macophylla* fruits. Asian J Chem, 8(3):1751-1758.
- Whitcomb DC, Block GD, 1994. Association of acetoaminophen hepatotoxicity with fasting and ethanol use. JAMA, 272(23):1845-1850.
- Yadav V, Jayalakshmi S, Singh RK, Patra A, Khan S, 2011. Preliminary assesment of anti-inflammatory activity of *Callicrpa macophylla* Vahl. leaves extracts. Indo-Global J Pharmaceut Sci, 1(3):219-222.